

# EVOLUTION OF A HETEROTOPIC HYPOPHYSEAL TRANSPLANT: IMAGENOLOGICAL RESULTS

\*Dra. Susana Alcázar Leyva. \*\*Dr. Paul Loewe. \*\*Dr. Carlos Lechuga. \*\*Dra. Edith Ortiz Guerrero.

Address for Mailing:  
Dra. Susana Alcázar Leyva  
Av. San Bernabé 416-100 d.  
Col. San Jerónimo  
C.P. 10200. México, D.F.

## SUMMARY

Evolution of a pig hypophysis transplant into the subcutaneous fat of a human being is described, as observed with radiology echograph and thermograph techniques. Radiology and echography showed progressive absorption of the transplanted tissue, but even after seven months, thermovascular activity was still found in and near the surgical bed. The possible significance of these findings is discussed.

## INTRODUCTION

Over the last nineteen years more than seven thousand subcutaneous transplants of suckling-pig hypophysis have been performed in human beings, using a technique which apparently prevents immunological rejection.<sup>1</sup> Although no macroscopic evidence of rejection has been observed, neither do we know of the final whereabouts and evolution of the transplanted tissue.

Indirect evidence suggests that the hypophyseal transplant does not stop being functional.<sup>2</sup> Nevertheless, no patient has undergone studies to determine the evolution of the transplant, neither with histological nor with invasive methods.

The purpose of this paper is to describe the evolution of a heterotopic hypophysis implant. Methods used for observation included radiological, ultrasound and thermographic techniques.

## CASE DESCRIPTION

A thirty-nine year old male, clinically healthy, was transplanted with the complete hypophysis from a suckling-pig in the subcutaneous tissue of the left deltoid area. The technique used to avoid rejection was that already described<sup>1</sup> and the evolution of the transplant was ascertained using three techniques: radiograph, ultrasound and thermograph. The results obtained are summarized in the following table:

Date	Radiograph	Thermograph	Ultrasound
Implant day	Annular density 3×5 mm attributed to encapsulated gland.	No hyperthermic manifestation	
After 4 days	Flattened ring 2×6 mm		Echolucidity of 7×11×18 mm
After 10 days	Flattened ring 3×6 mm	Focal hyperthermia as an oval stain	
After 18 days	Annular image fades, dense tissue forms. Thickening of skin	Hyperthermic stain acquires star-shape	Echolucidity of 7 mm
After 26 days	Fusiform transparency appears		
After 34 days	Spindle image now 2×6 mm	Star-shaped stain continues	Echolucidity disappears
After 224 days	Spindle reduced to 4 mm	Convergent thermo vascular image	No response

\* Hans Selye Institute of Scientific Research  
\*\* Clinical Radiology Unit

## DISCUSSION

Radiograph and echograph images would suggest that the absorption of transplanted tissue is gradual, without inflammatory response. It is remarkable that, even after 224 days, thermovascular activity persists, concentrated in the surgical bed itself. Although it seems obvious that the gland as such has

disappeared, the persistence of the thermovascular image is compatible with the presence of functional hypophyseal cells scattered throughout the tissue. It is therefore imperative to carry out histological studies—preferably using techniques such as immunofluorescence or immunohistochemistry which detect the presence of hypophyseal hormones—in order to confirm or to refute this possibility.




**Fig. 1**

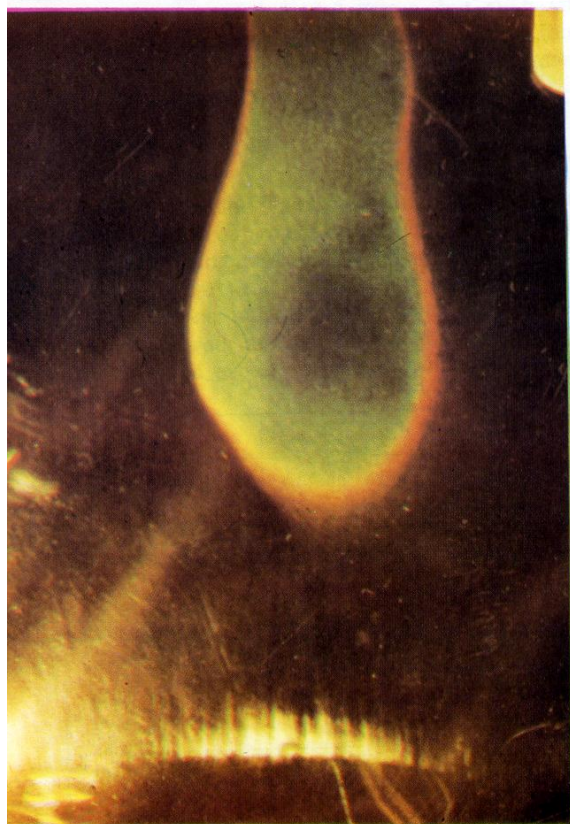
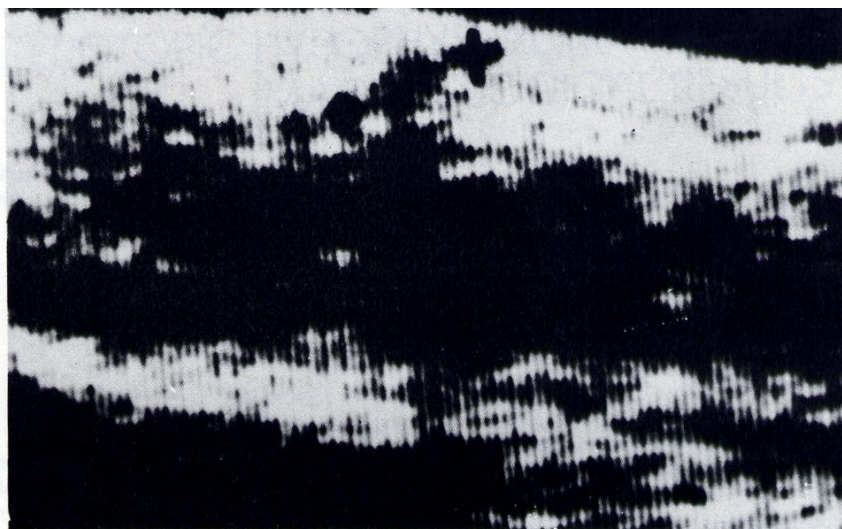
*Radiological image showing annular density of 3×5 mm (arrowed) attributed to the encapsulated gland.*

**Fig. 2**

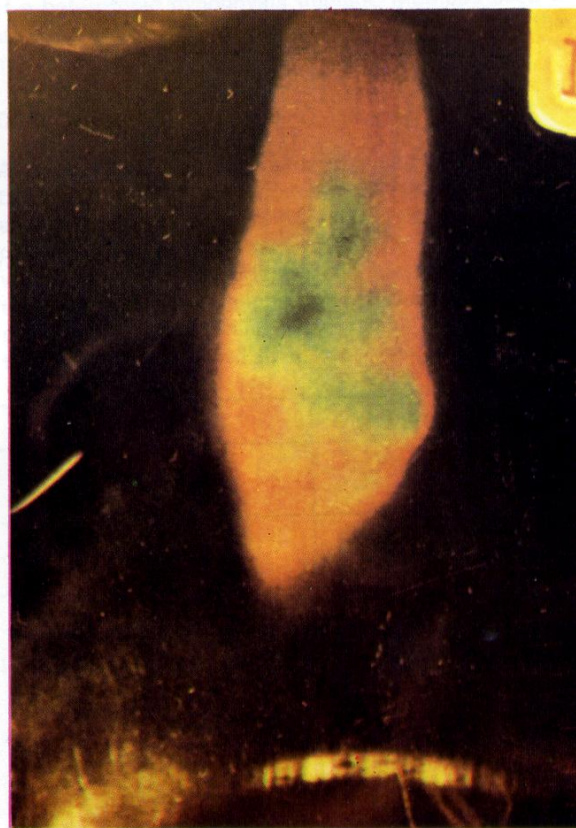*Fusiform radiological image after 34 days.*



**Fig. 3**  
 Imagen ecográfica a los 4 días.  
 Se observa una zona de  
 ecolucidez de  $7 \times 11 \times 18$   
 mm.



**Fig. 4**  
 Imagen termográfica a los 10 días. Se observa hipertermia  
 en forma de una mancha ovalada de color verde.



**Fig. 5**  
 Imagen termográfica a los 18 días. Se observa hipertermia  
 en forma de una mancha estelar de color verde.

#### REFERENCIAS

1. Manuell S., Alcázar S.: Una nueva técnica geriátrica. *Semana Médica de México* (1982) **XCIX**: 175-183.
2. Alcázar-Leyva S., Quintanilla M. L. Gayoso R.: Heterotransplante heterotópico de hipófisis de cerdo lactante a paciente hipofisectomizado por craneofaringioma. *Semana Médica de México* (1985) **CII**: 118-122.